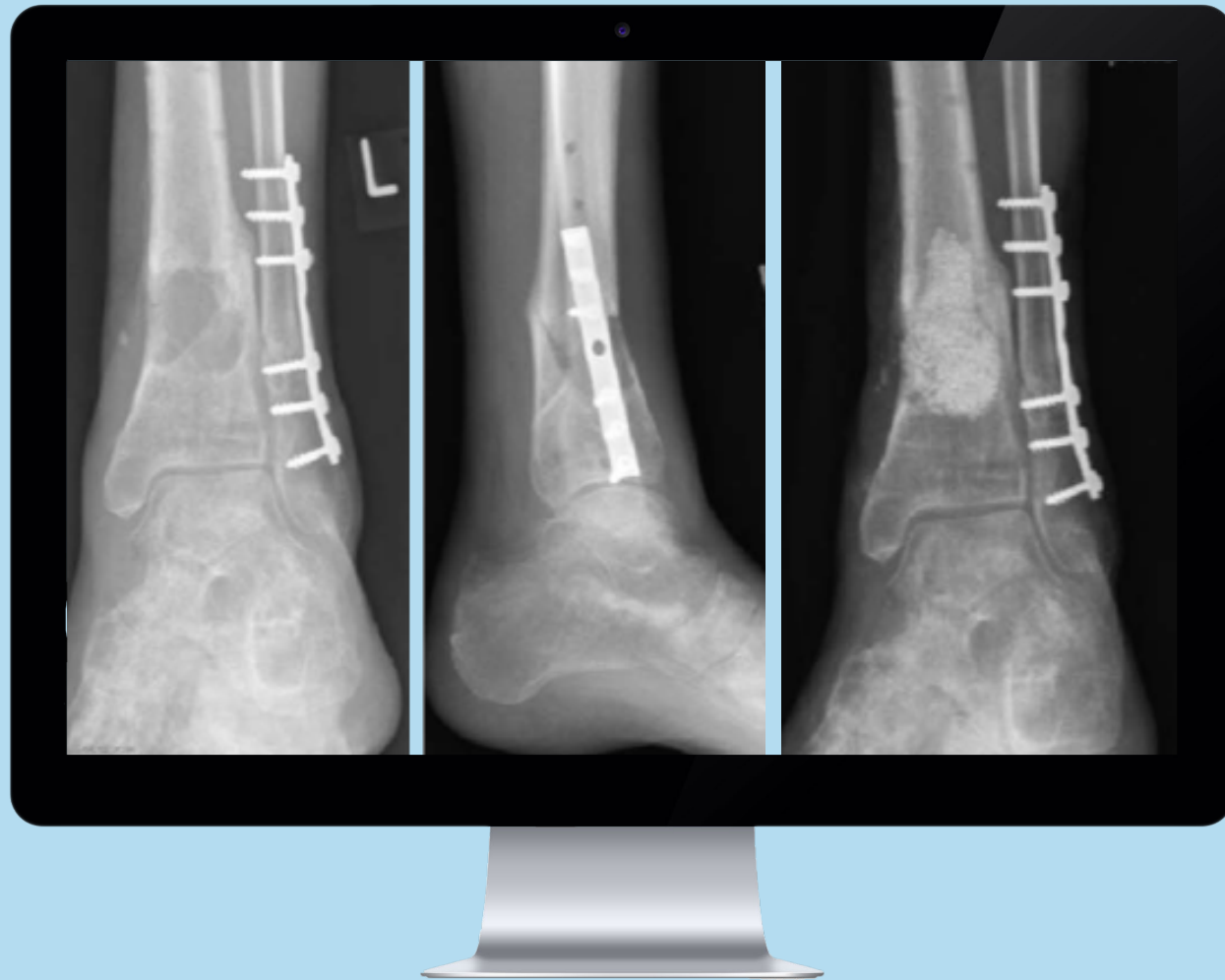

**Indication
of the**

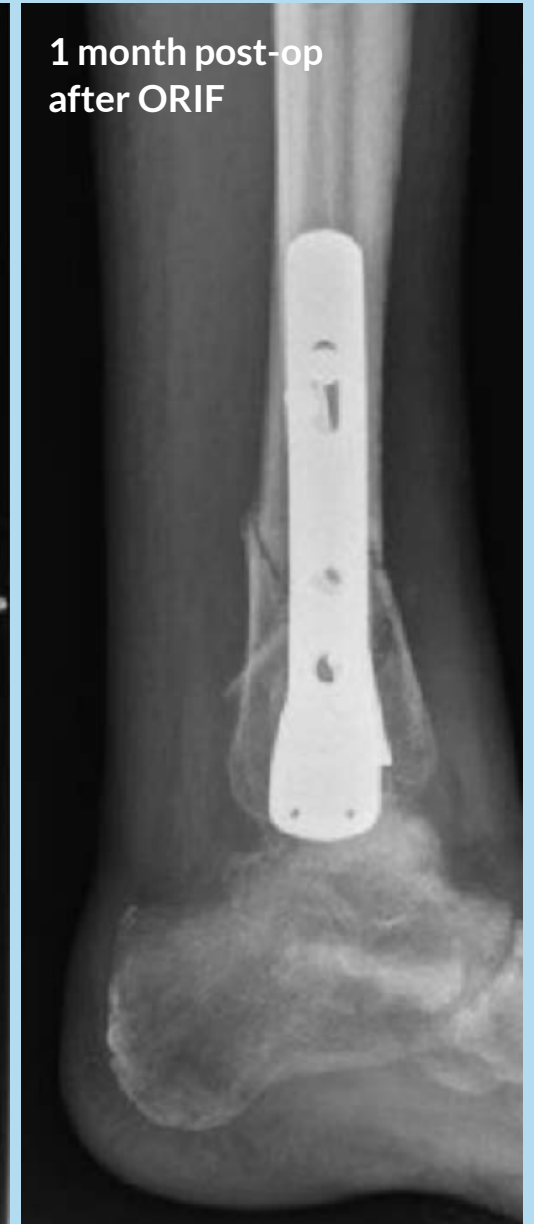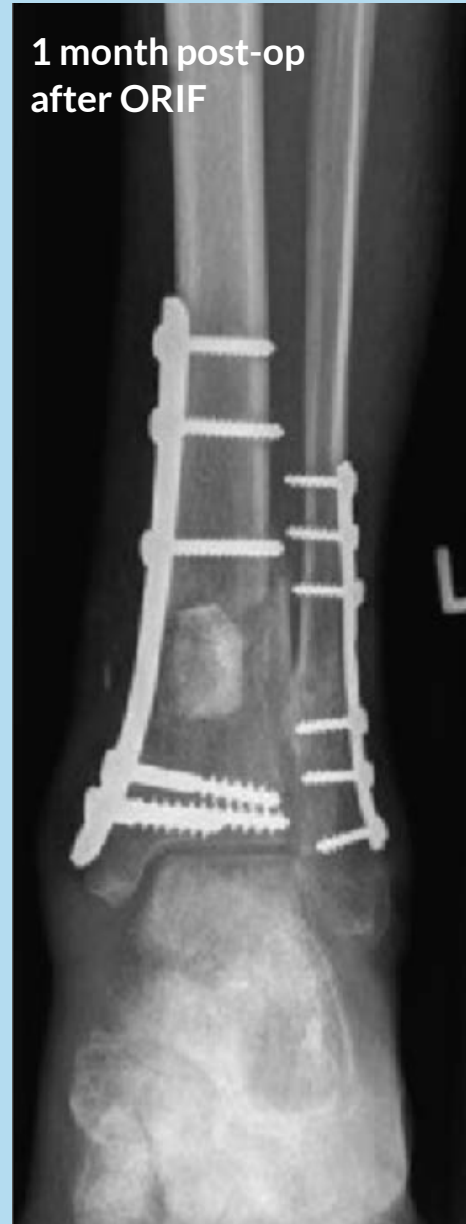q

Septic non-union in distal tibia

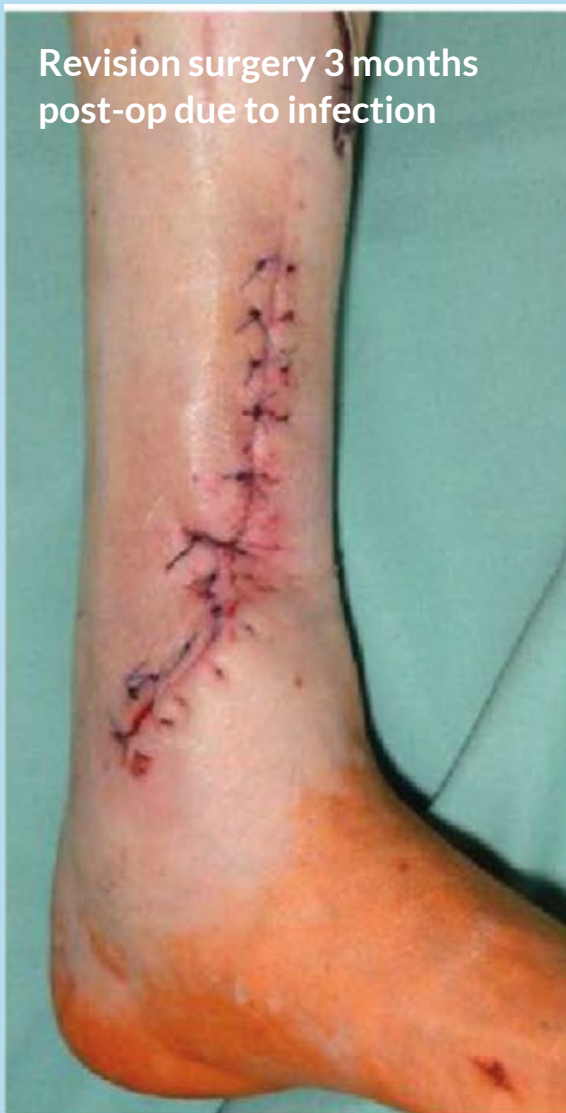Patient

61-year-old male. Closed distal tibia fracture with affected Pilon tibiale. Infection of the tibial plate 3 months after Open Reduction Internal Fixation (ORIF).

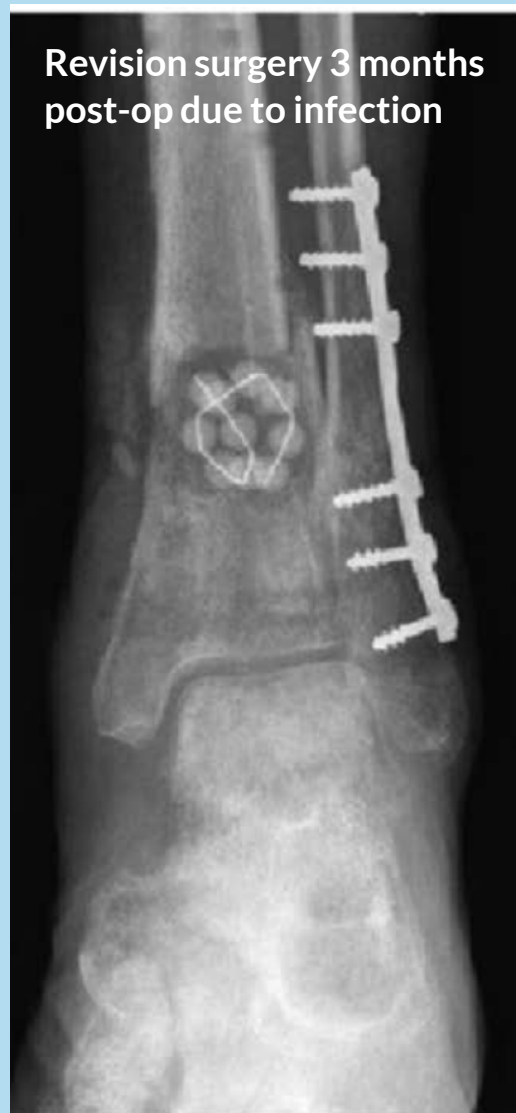Bacterial culture: *Staphylococcus aureus* and *Staphylococcus epidermidis*



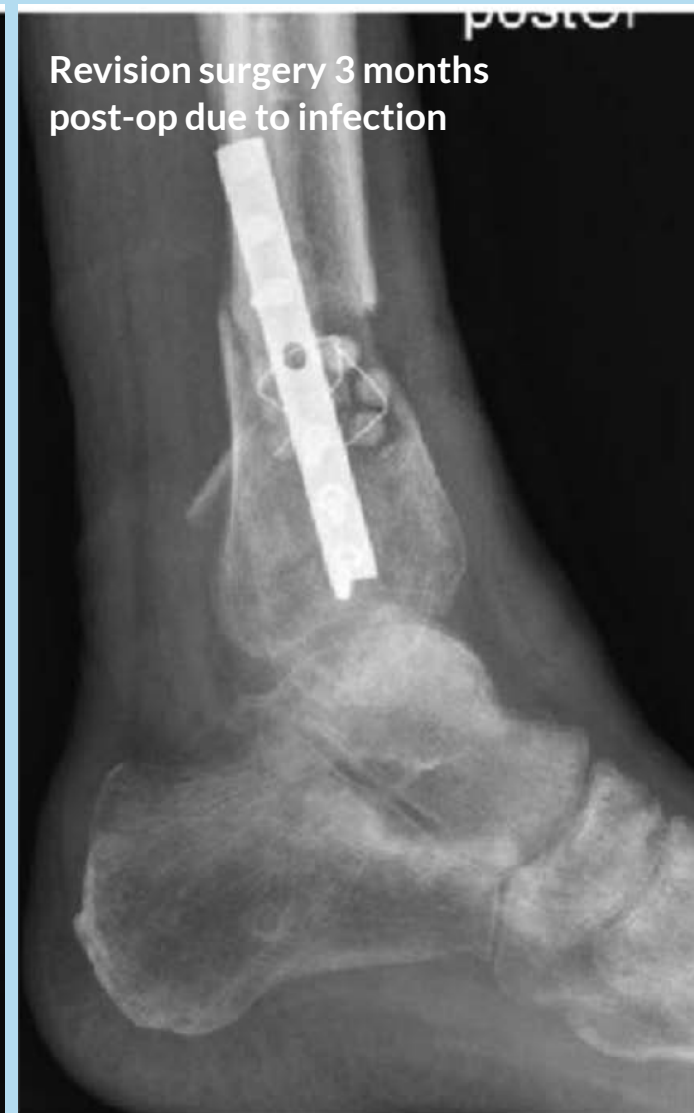Revision surgery 3 months
post-op due to infection



Revision surgery 3 months
post-op due to infection

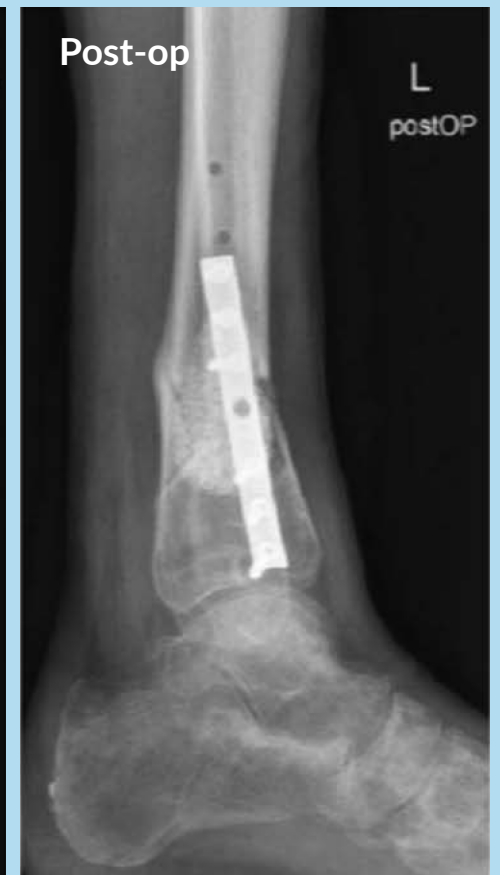
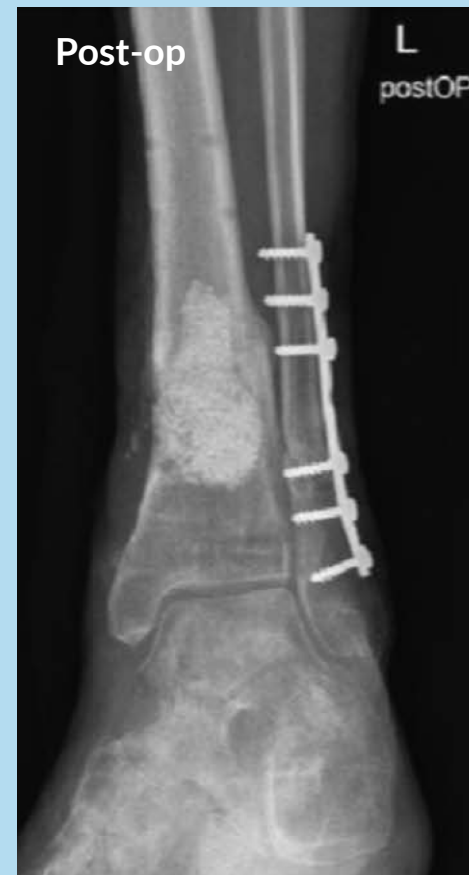
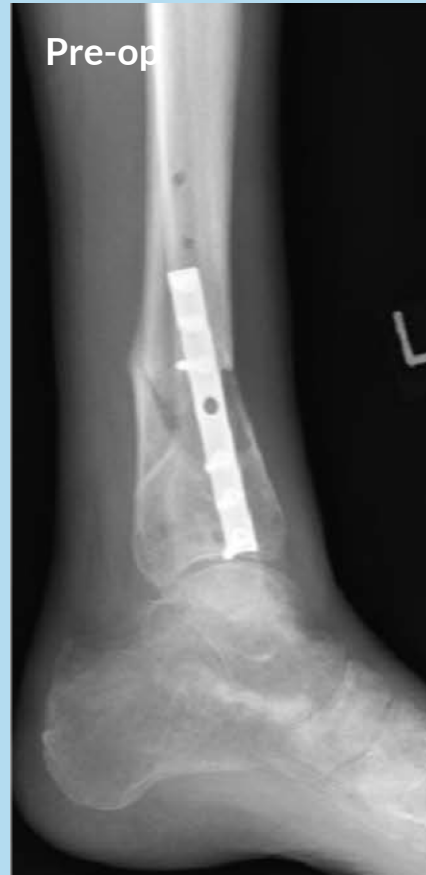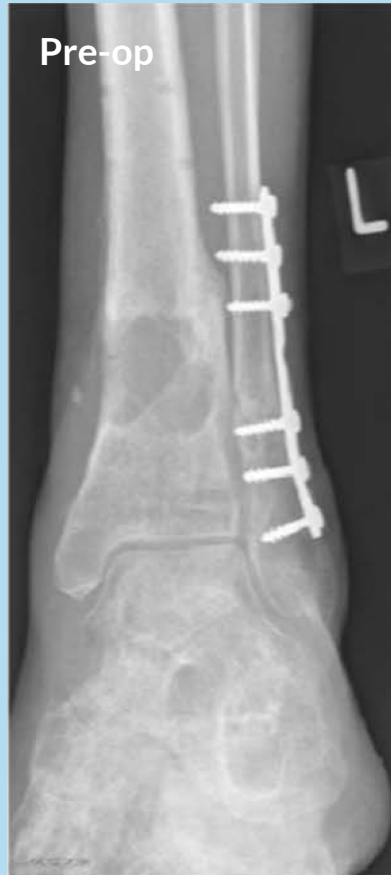Revision surgery 3 months
post-op due to infection



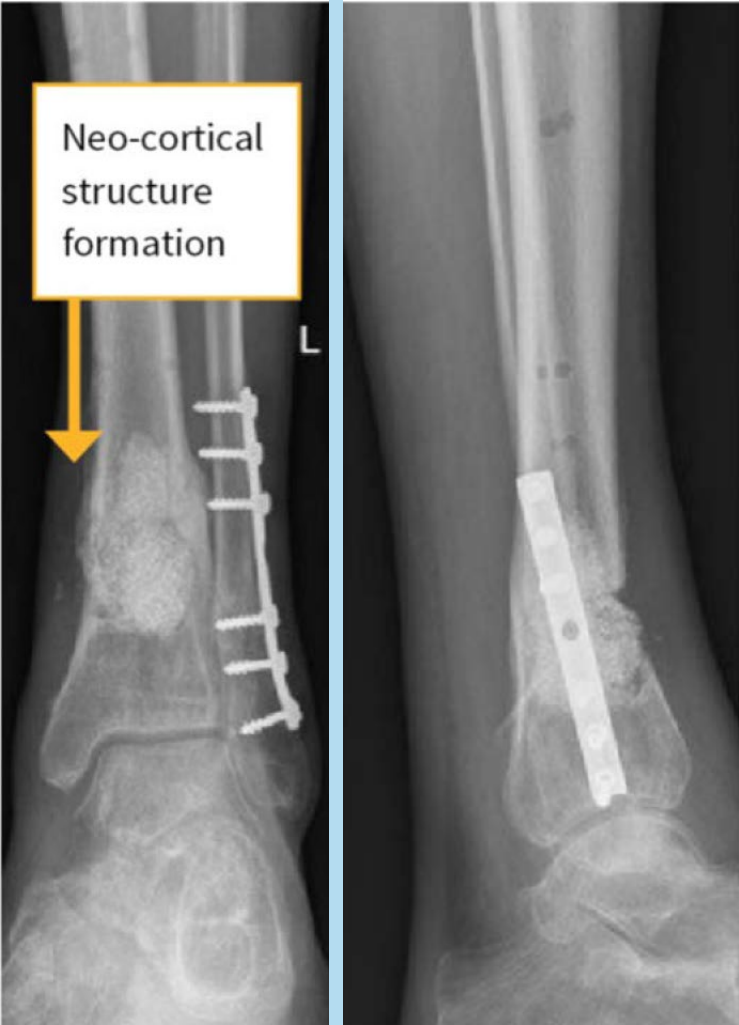Operation

Removal of the antibiotic releasing beads after 6 weeks and implantation of 20 cc bioactive glass.

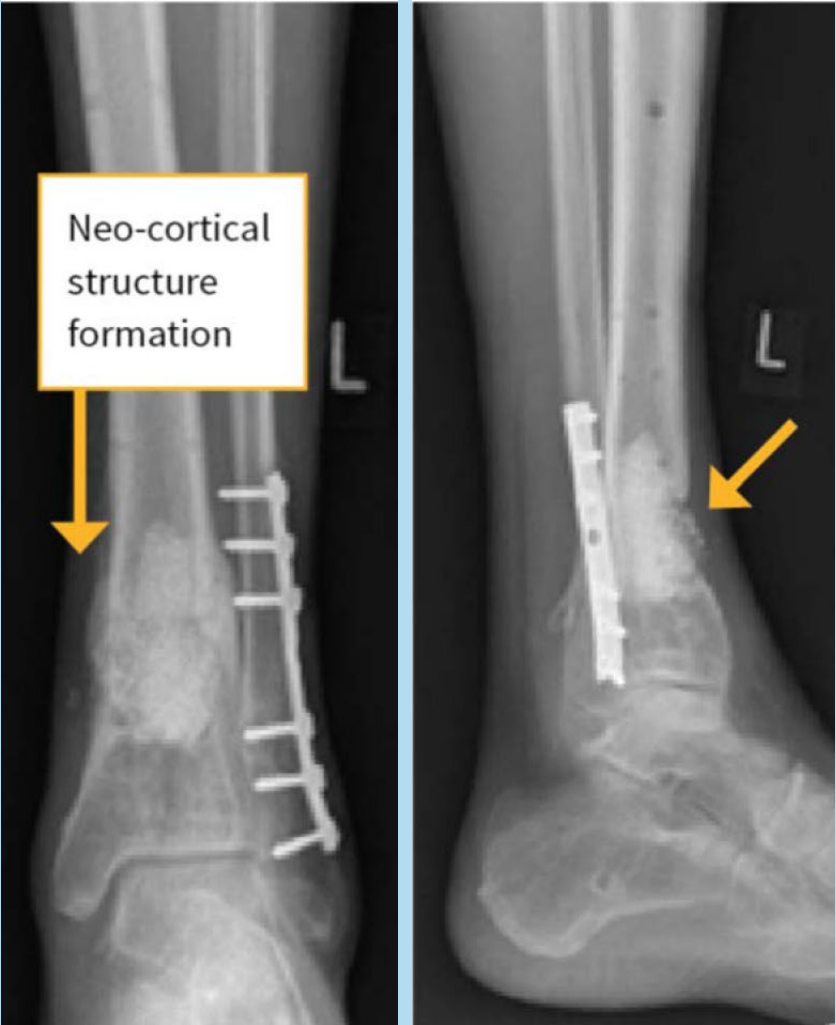

Bone formation can be observed 2 months and 4 months after treatment.

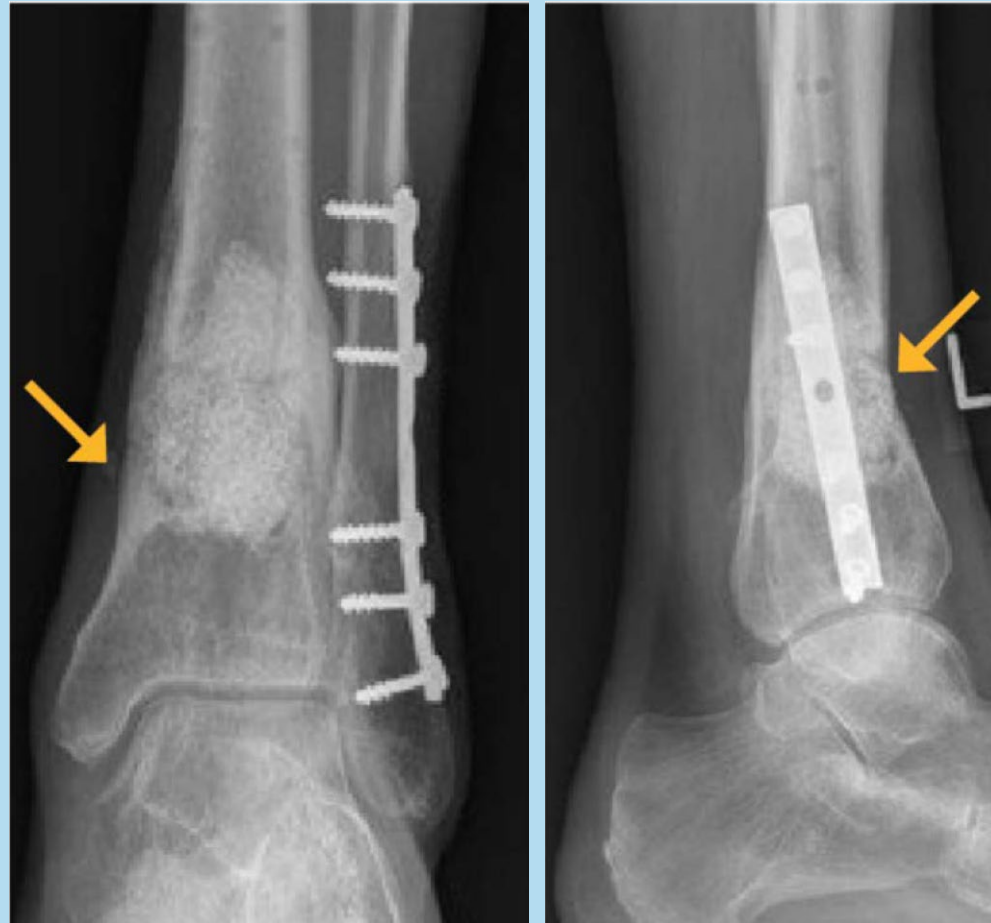
2 months post-op



4 months post-op



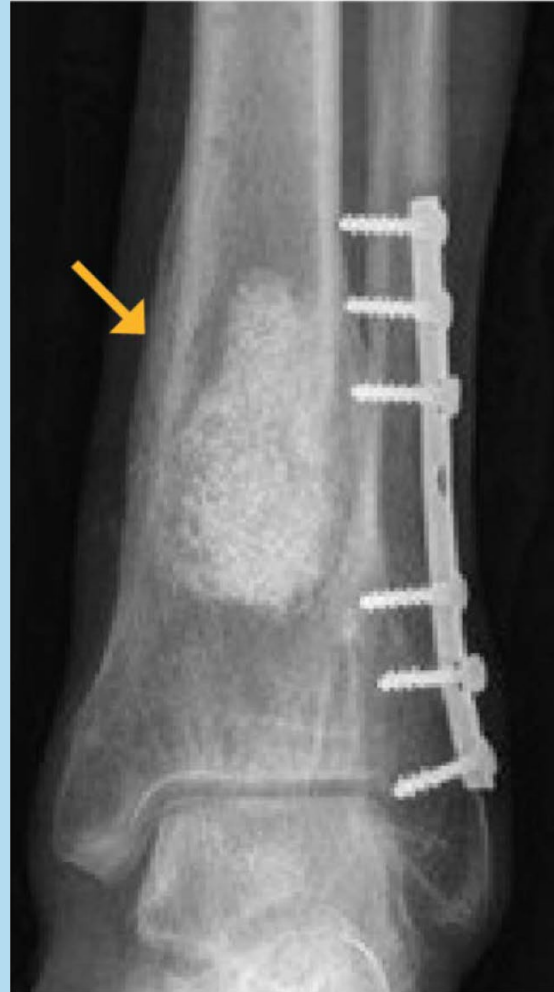8 months post-op



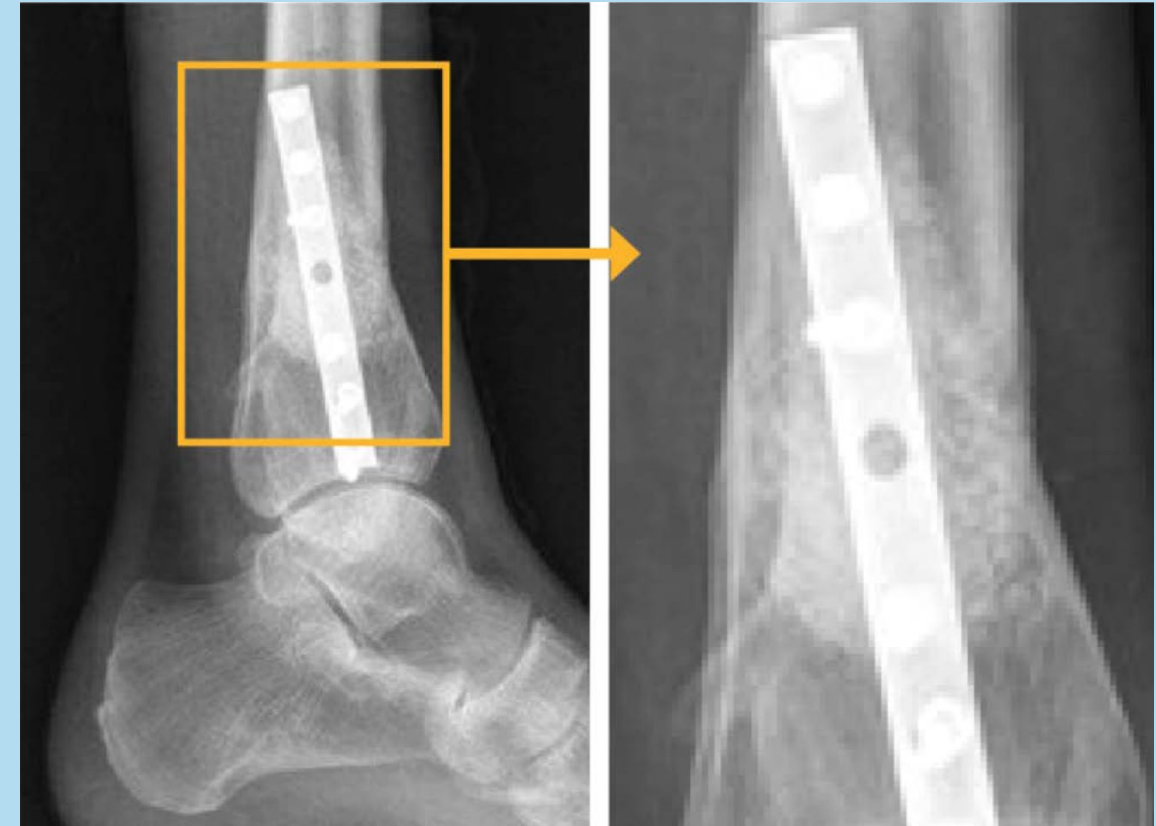
Clinical outcome

Periosteal reaction resembling a “neo-cortical-structure” is visible in the anterior region where bioactive glass has been implanted.

14 months post-op



14 months post-op



See more cases
in the Smart
Healing Center:
smarthealing.center

